

Idiopathic osteosclerosis of the jaws on panoramic radiographic analysis in Indonesian Sub- Population

by Irfan Sugianto

Submission date: 18-Apr-2023 09:06PM (UTC+0700)

Submission ID: 2068332005

File name: 01_jdmfsv7i21339.pdf (546.09K)

Word count: 2762

Character count: 14612

Idiopathic osteosclerosis of the jaws on panoramic radiographic analysis in Indonesian Sub-Population



CrossMark

Irfan Sugianto^{1*}, Barunawaty Yunus, Fadhil UA. Rahman, Muliaty Yunus, Dwi P. Wulansari, Muhammad F. Hidayat

Abstract

Objective: To determine prevalence of Idiopathic osteosclerosis (IO) by radiographic evaluation and to investigate the relationship between the finding in relation with age, gender and location in Indonesia Sub-Population.

Material and Methods: This was a cross-sectional study that panoramic radiograph of patients (1030 male and 1914 female) whose age range 10-82 years old and who visited Department of Oral and Maxillofacial Radiology Hasanuddin University Dental Hospital from 2017 and 2020. We evaluated group of age, location, appearance and occurrence of IO and analyzed using chisquare test.

Results: in total, 2944 panoramic radiographs were examined, IO

found in 144 (4.8%) patients and 170 IO's were detected mostly in mandible than maxilla ($p < 0.005$) where premolar and molar area was the most common location of IO (42.3% and 41.7%; respectively). Most of cases was solitary lesion (< 0.005) and unilateral (< 0.005). In addition, most of IO separate from teeth (45.8%) and also related with periapical sites (35.3%).

Conclusion: Idiopathic Osteosclerosis can defined as developmental variation that can occur in any age range, no predilection of sex. The frequency of IO in Indonesia Sub-population is slightly lower than other country.

Keywords: ESR, Periodontitis (MeSH), PISA, Platelet count (MeSH), Type 2 diabetes mellitus (MeSH)
DOI: 10.15562/jdmfs.v7i2.1339

³ Department of Oral Radiology,
Faculty of Dentistry Hasanuddin
University, Makassar, Indonesia

Introduction

Idiopathic osteosclerosis (IO) is radiopacity in cancellous bone in body skeleton including jawbone that the cause of this lesion still unknown. Idiopathic osteosclerosis is asymptomatic and usually incidentally finding in routine radiograph examination such as panoramic radiograph and Cone beam Computed Tomography (CBCT) on various size and shape without cortical expansion. Range of size is from 1 mm to 1 to 3 cm however there was a case reported the size was 7 cm¹, the IO could associate with teeth or separate with different appearance with normal trabecular bone. Most of cases are occur in mandible, premolar and molar site is the most area of IO². Dense bone island, enostosis and focal periapical osteopetrosis are the other name of IO³. In several studies if IO showed hyperradiopaque appearance in jaw bone mostly demonstrate pathologic condition in panoramic radiograph⁴. There are other types of radiopaque in jaw bone such as condensing osteitis, focal cemento-osseous dysplasia, osteoma and exostosis could related to inflammation and trauma, fibro-osseous benign and overgrowth of bone. Although several previous study reported the morphometric of IO in different population^{3,6,8-12}, this study will enrich the understanding and provide the characteristic of IO especially in sub-population in Indonesia.

Material and Methods

We review 2954 panoramic radiographs of outpatients with in Hasanuddin University Dental Hospital from 2017 and 2021 whose age was 10-82 years old, and we excluded 10 patients due to the distortion and error of patient position. All the images was taken use our panoramic Xray modality (Soredex Panoramic X-mind Pano D + cep; Finland); 73kV, 10mA, 20 seconds scan time. The images examination conducted by IS and examination using digital imaging of panoramic directly in computer and using default contrast and sharpness of the images. The image evaluation was performed maximum 50 images per day and repeated twice after all images was evaluated. We evaluate all the image except Images with distortions, error of patient's position and patients under 10 years old.

Radiographic criteria of idiopathic osteosclerosis

1. Well-defined radiopacity in jawbone that located surround the teeth, connect with teeth that have no caries or have small restoration or separate with teeth
2. The radiopacity related with teeth is free caries at least enamel caries or small restoration
3. There is no endodontics treatment

Correspondence to: Irfan Sugianto,
Department of Oral Radiology,
Faculty of Dentistry Hasanuddin
University, Makassar, Indonesia
sugiantoirfan@gmail.com

Received 27 January 2022
Revised 19 February 2022
Accepted 15 March 2022
Available online 1 August 2022

⁷
<http://jdmfs.org>

4. The size more than 3 mm diameters
5. Without radiolucent rim

We excluded some lesion with following condition

1. Mixed lesion of radiopaque and radiolucent
2. Radiolucent with radiolucent rim
3. Chronic inflammation related with the teeth
4. Rest of deciduous or permanent teeth
5. Other identified bone conditions such as tori exostosis

Radiographic Investigation of idiopathic osteosclerosis

We evaluated location, internal structure, position of radiopaque in panoramic radiograph. We grouping the IO based on the relation with teeth structure 1) apical 2) inter-radicular of apical, 3) interradicular 4) separate with teeth. We identified whether IO unilateral or bilateral and solitary and multiple.

Statistical analysis using SPSS (11.5; Chicago, IL, USA) to determine the differences of IO distribution which defined by number, group of age, region (maxilla/mandible, unilateral/bilateral), location and condition (solitary/multiple), relationship to teeth, group of age, and gender. The Chi-squared test was used to analyze the IO distribution that statistical significance consider with p value <0.005.

Results

In this study we evaluated panoramic radiograph of 2954 patients, We excluded 10 patients due to the distortion and error of patient position. aged 10-75 years. We identified radiopaque in jaw bone in 144 patients (60 male and 84 female) and showed predilection of sex ($p > 0.005$) and the age mean is 30.2 years. We found unilateral lesion in 126 patients (87.5%) and 18 patients (12.5%) in bilateral of mandible ($p < 0.005$). Most of patient's cases were solitary lesion (122 lesions; 84.7%) and the rest of lesion were multiple (22 lesions; 15.3%) ($p < 0.005$). The IO cases finding showed that The third decade is the most finding of a group of IO. Eighteen cases (12.5%) in 10 to 20 years of age, 70 cases (48.6%) in 21 to 30 years of age, 32 cases (22.2%) in 31 to 40 years of age, 15 cases (10.4%) in 41 to 50 years of age, six cases (4.1%) in 51 to 60 years of age, one case (0.7%) in 61 to 70 years of age and two cases (1.3%) in over 70 years of age **Table 1**.

In this study, location of IO cases is 168 cases in mandible and two cases in maxilla ($p < 0.005$). The appearance region of IOs is equal distribution of

molar and premolar region which 72 cases (42.3%) occur in molar area, 71 cases (41.8%) occur in premolar area and the rest of cases, 27 cases (15.9%) occur in anterior area. In this study we identified 170 IOs in defined location of IOs in four areas; Associate with apices, inter radicular in apical area, inter radicular of proximal area of the apices and separate from teeth **Figure 1**. Most of IOs was separate from teeth, we found 78 (45.9%) cases were separate from teeth, 60 (35.3%) cases in associate with apices, 30 (17.6%) cases in inter radicular in apical area and two (1.2%) cases located in inter radicular of proximal area of the apices ($p < 0.005$) **Table 2**.

Discussion

Idiopathic Osteosclerosis (IO) usually incidentally found in routine radiograph examination without symptoms, with there is no tendency to growth but a few study reported that there were enlargement of IO size and need a treatments^{13,14}. Most of cases has no need special treatment, however, the regular evaluation through radiograph examination to monitor whether the IO shown the size and shape change. The IO is not shown clinical implication, however in implant treatment need an evaluation pre and post treatment¹⁵.

The cause of IO is unclear, some theories mention that the cause of IO was developmental bone variation and was not related with trauma or dental problem. The previous studies reported that prevalence of IO was varies from 0.15 -19.5%²⁻¹², in our imaging analysis showed that the IO prevalence was 4.9%. We noted that high occurrence is on female on the second decade, on the other study reported that the occurrence of IO was third decade^{4,6,7} and the fourth decades^{3,3,5}. In all studies showed that IO mostly occur on mandible and molar and premolar are most occurrence area of IO³⁻¹¹. Several studies were conducted on various population, races or country, however the result of that studies shown that the IO is not predilect on specific races. In some studies, shown the predilection of IO associated with location, ages and gender⁴⁻⁷. Our study is in line with most studies related to location of IO that the apical and separate with teeth area is the most site of IO and premolar and molar of mandible are most site²⁻¹². Our finding also showed most of IO occur unilateral and solitary lesion although could occur bilateral and multiple.

Identification of IO is very important in radiograph interpretation, radiopacity in jawbone could provide essential information of pathologic condition. The radiopacity surround of teeth with

Table 1 The patient data with IO related to sex, occurrence, appearance and group of age

		Number of cases	Percentage	p value
Sex	Male	60	15.9%	6 $P > 0.005$
	Female	84	41.8%	
Occurrence	Unilateral	126	87.5%	$P < 0.005^*$
	Bilateral	18	12.5%	
Appearance	solitary	122	84.7%	$P < 0.005^*$
	Multiple	22	15.3%	
Group of Age	10-20	18	12.5	$P < 0.005^*$
	21-30	70	48.6	
	31-40	32	22.2	
	41-50	15	10.4	
	51-60	6	4.1	
	61-70	1	0.7	
	>70	2	1.3	

radiolucent border and usually occur in bilateral are in the anterior mandible (ref POD), similar with IO, POD also occur in vital teeth, sometimes radiolucent border are not seen so that difficult to distinguish with IO.

The radiopacity in jawbone also could a mixed benign odontogenic such as odontoma, the appearance of odontoma is radiopaque with radiolucent border in jawbone and usually associate with impacted teeth¹⁹. The distinguish between IO and odontoma is not to difficult because IO usually not relate with impacted teeth and without radiolucent border. The other benign that demonstrated radiopaque appearance is benign cementoblastoma. Cementoblastoma also shown radiopaque in apical and usually in vital teeth without abnormal condition in the crown area. The radiopacity of benign cementoblastoma is merged with apex structure dan surrounding with radiolucent rim. Differentiation between IO and benign cementoblastoma could be with identification of radiolucent rim, IO usually shown cortical border without radiolucent rim²⁰.

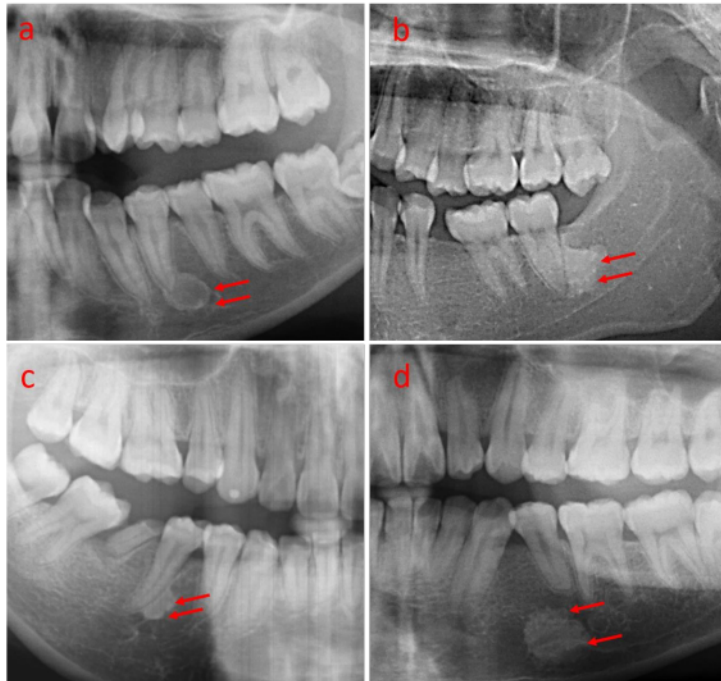
Table 2 The IO's distribution related to location and occurrence

Idiopathic osteosclerosis	Number of lesions	Percentage	Significance level
Maxilla	168	98.8%	6 $P < 0.005^*$
Mandible	2	1.2%	
Anterior	27	15.9%	$P < 0.005^*$
Premolar	71	41.8%	
Molar	72	42.3%	
Associate with apices	60	35.3%	$P < 0.005^*$
Inter radicular in apical	30	17.6%	
Inter radicular of proximal area of the apices	2	1.2%	
Separate from teeth	78	45.9%	

deep and deep caries or teeth with endodontic treatment could periapical sclerosing osteitis¹². Periapical sclerosing osteitis is the increasing of bone calcification surround periapical area that the reaction of chronic infection. Periapical sclerosing osteitis usually cause the caries extension until the pulp or in teeth with endodontic treatment, widening of peridontal ligament and radiopacity is higher than normal alveolar bone^{16,17}. The other pathologic condition is Periapical Osseous Dysplasia (POD) especially in mature stage^{17,18}. The POD demonstrated radiopaque in periapical area with

Most of IO occur in premolar and molar region, one of the radiopaque appearance in premolar and molar area could resembling IO is sialolithiasis. Sialolithiasis is the condition of obstruction of salivary ducts which shown swelling in the mouth floor and accompanied with pain²¹. In panoramic examination, when sialolith superimposed in apical of premolar or molar, it will slightly difficult to distinguish with IO. The identification of sialolithiasis could be prove with occlusal radiograph, the radiopaque mass shown in the mouth floor and separate with jawbone.

Figure 1 Idiopathic osteosclerosis showed homogenous radiopaque with clear border: (a) associate with apical. (b) apical area. (c) interradicular of proximal area of the root. (d) separate with teeth



The identification of IO is essential to distinguish with other radiopaque lesions. In this study we discover the characteristic of IO from the radiograph examination and showed similar result with other studies. The limitation of this study is radiograph examination use a single method of radiograph. On the future study, using advance modalities such as CBCT and MDCT could provide comprehensive result of IO evaluation.

Acknowledgment

No acknowledgement

Conflict of Interest

The authors report no conflict of interest.

References

1. Ledesma-Montes C, Jimenez-Farfan MD, Hernandez-Guerrero JC. Maxillomandibular giant osteosclerotic lesions. *J Appl Oral Sci* 2018;26: 1-8.
2. Gamba TO, Maciel NAP, Rados PV, et al. The imaging role for diagnosis of idiopathic osteosclerosis: A retrospective approach based on record of 33.550 cases. *Clin Oral Investig* 2021;25: 1755-1765.

3. Kawai T, Hirakuma H, Murakami S, et al. Radiographic investigation of idiopathic osteosclerosis of the jaws in Japanese dental outpatient. *Oral surg oral med oral pathol* 1992; 74: 237-242.
4. Sisman Y, Ertas ET, Ertas H, et al. The frequency and distribution of idiopathic osteosclerosis of the jaw. *Eur J Dent* 2011;5: 409-414.
5. Yonetsu K, Yuasa K, Kanda S, et al. Idiopathic osteosclerosis of the jaws panoramic and computed tomographic findings. *Oral Surg Oral Med Oral Pathol Oral Radiol Endod* 1997;83: 517-521.
6. Wang S, Xu L, Cai C, et al. Longitudinal investigation of idiopathic osteosclerosis lesion of the jaw in a group of Chinese orthodontically-treated patients using digital panoramic radiography. *J Dent Sci* 2022;17: 113-121.
7. McDonnell M. Dense bone island a review of 107 patients. *Oral Surg Oral Med Oral Pathol* 1993;76: 124-128.
8. Solanki J, Jain R, Singh R, et al. Prevalence of osteosclerosis among patients visiting dental institute in rural area of Western India. *J Clin Diagn Res* 2015;9: 38-40.
9. Fuentes R, Arias A, Astete N, et al. Prevalence and morphometric analysis of idiopathic osteosclerosis in a Chilean population. *Folio Morphol* 2018;77: 272-278.
10. Miloglu O, Yalcin E, Cemil-Buyukkurt, et al. The frequency and characteristic of idiopathic osteosclerosis and condensing osteitis lesions in a Turkish patient population. *Med Oral Patol Oral Cir Bucal* 2009;14: 640-645.
11. Moshfeghi M, Azimi F, Anvari M. Radiologic assessment and frequency of idiopathic osteosclerosis of jawbones: an interpopulation comparison. *Acta radiol* 2013;55: 1239-1244.
12. Farhadi F, Ruhani MR, Zarandi A. Frequency and pattern of idiopathic osteosclerosis and condensing osteitis lesion in panoramic radiography of Iranian patients. *Dent Res J* 2016;13: 322-326.
13. Kawai T, Murakami S, Kishino M, et al. Gigantic dense bone island of the jaw. *Oral Surg Oral Med Oral Pathol Oral Radiol Endod* 1996;82: 108-115.
14. Mariani GC, Favaretti F, Lamazza L, et al. Dense bone island of the jaw: a case report. *Oral Implantol* 2008;8: 87-90.
15. Li Z, Lai R, Feng Z. Case history report: cone beam computed tomography for implant insertion guidance in the presence of a dense bone island. *Int J Prosthodont* 2016;29: 186-187.
16. Silva BSE, Bueno MR, Tamamoto-Silva FP, et al. Differential diagnosis and clinical management of periapical radiopaque/hyperdense jaw lesions. *Braz Oral Res* 2017;31: 1-20.
17. Cure JL, Vattoth S, Shah R. Radiopaque jaw lesions: an approach to the differential diagnosis. *Radiographics*. 2021;32: 1-10.
18. Nadler C, Perschbacher SE, Septon B, et al. Important radiographic features in the identification of osseous dysplasia-related osteomyelitis. *Oral Surg Oral Med Oral Pathol Oral Radiol* 2021;131: 730-737.
19. Nelson BL, Thomson LDR. Compound odontoma. *Head Neck Pathol* 2010;4: 290-291.
20. Chrchanovic BR, Gomez RS. Cementoblastoma: An updated analysis of 258 cases reported in the literature. *J Cranio-Maxillo-Fac Surg* 2017;45: 1759-1766.
21. Bar T, Zagury A, London D, et al. Calcifications simulating sialolithiasis of the major salivary glands. *Dentomaxillofac Radiol* 2014;36: 1-7.



This work is licensed under a Creative Commons Attribution

Idiopathic osteosclerosis of the jaws on panoramic radiographic analysis in Indonesian Sub-Population

ORIGINALITY REPORT

13%

SIMILARITY INDEX

11%

INTERNET SOURCES

6%

PUBLICATIONS

5%

STUDENT PAPERS

PRIMARY SOURCES

1	www.semanticscholar.org Internet Source	2%
2	www.ncbi.nlm.nih.gov Internet Source	2%
3	Submitted to Universitas Negeri Semarang Student Paper	1%
4	Submitted to Universitas Hasanuddin Student Paper	1%
5	pdfs.semanticscholar.org Internet Source	1%
6	Silvia Lorincová, Miloš Hitka, Peter Štarchoň, Katarína Stachová. "Strategic Instrument for Sustainability of Human Resource Management in Small and Medium-Sized Enterprises Using Management Data", Sustainability, 2018 Publication	1%
7	repository.unhas.ac.id Internet Source	1%

8	exodontia.info Internet Source	<1 %
9	koreascience.or.kr Internet Source	<1 %
10	link.springer.com Internet Source	<1 %
11	Kazuhiko Nakano, Kazuyo Fujita, Rena Okawa, Ryota Nomura, Hidekazu Sasaki, Takashi Ooshima. "Dense bone island in mandible with 8 years of follow-up examinations", <i>Pediatric Dental Journal</i> , 2007 Publication	<1 %
12	Yildiray Sisman, Elif Tarim Ertas, Huseyin Ertas, Ahmet Ercan Sekerci. "The Frequency and Distribution of Idiopathic Osteosclerosis of the Jaw", <i>European Journal of Dentistry</i> , 2019 Publication	<1 %
13	www.acarindex.com Internet Source	<1 %
14	www.scribd.com Internet Source	<1 %
15	www.thieme-connect.de Internet Source	<1 %

Exclude quotes On

Exclude matches < 5 words

Exclude bibliography On